

Advanced Endoscopy Video Presentations

Simon K. Lo, MD
Director of Endoscopy
Director, Pancreatic Diseases
F. Widjaja Family Chair in Digestive Diseases
Clinical Professor of Medicine
Cedars-Sinai Medical Centers
Los Angeles, California



Cholangioscopic polypectomy

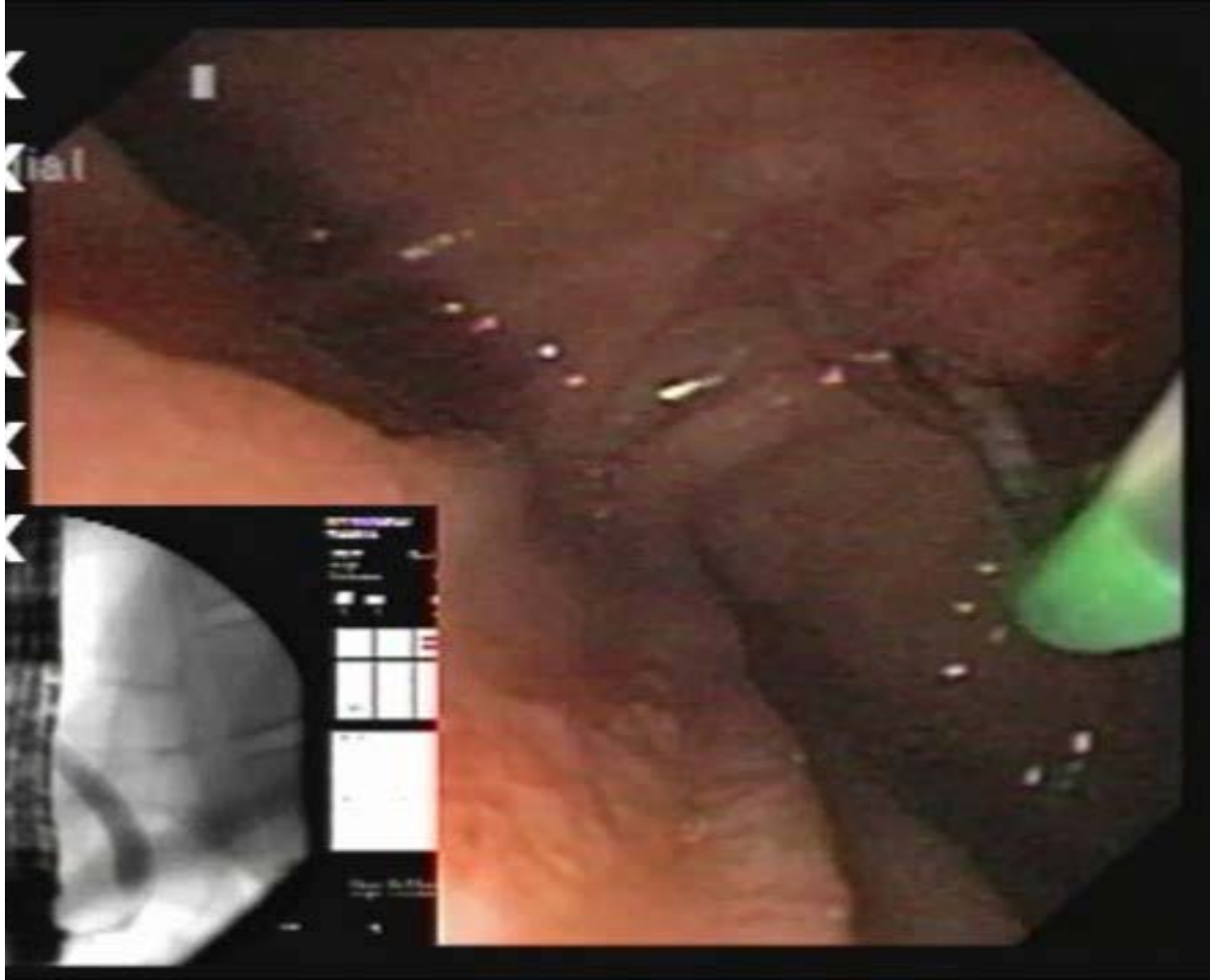
Lionel S. D'Souza, M.D
Petros C. Benias, M.D
David Carr-Locke, M.D



Discussion

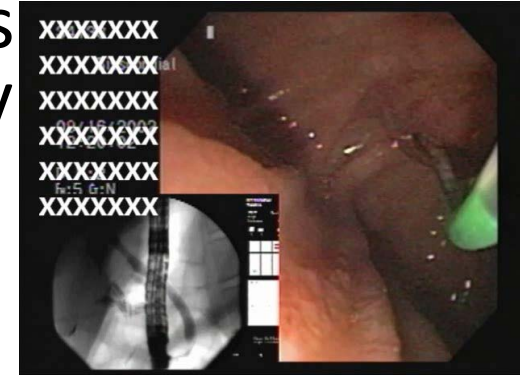


28 yo female with CBD stones



28 yo female with CBD stones

- After the sphincterotomy, there was massive fresh bleeding. Fluoroscopy revealed retroperitoneal air.
- Vital signs were stable



What should be done now?

- Stop the procedure and call surgery
- Stop the procedure and call IR
- Try to stop bleeding
- Insert biliary stent
- Place an NG tube

ERCP bleed/perforation: what was done?

- Surgeon called, but was asked to stand by only
- Balloon tamponade done for 10 minutes
- Metal stent place across the sphincter
- Saline injection to reinforce the tissue around the stent for hemostasis
- Nasoduodenal suction tube placed before finishing the procedure
- Antibiotic treatment/type and cross x 2 units
- Did well without anything else done. Discharged after 4-5 days hospital stay!



Discussion

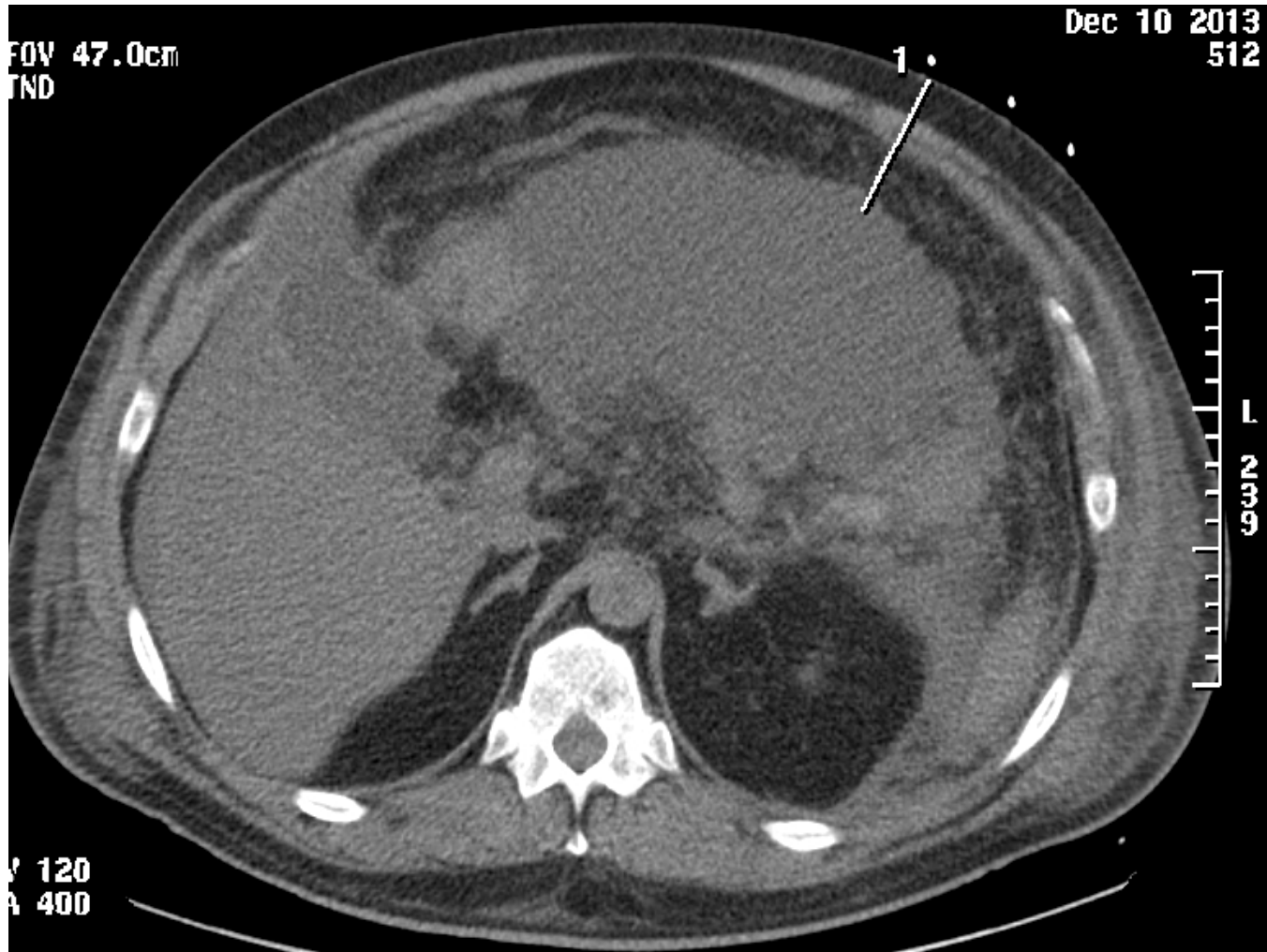


58 year old male with acute pancreatitis

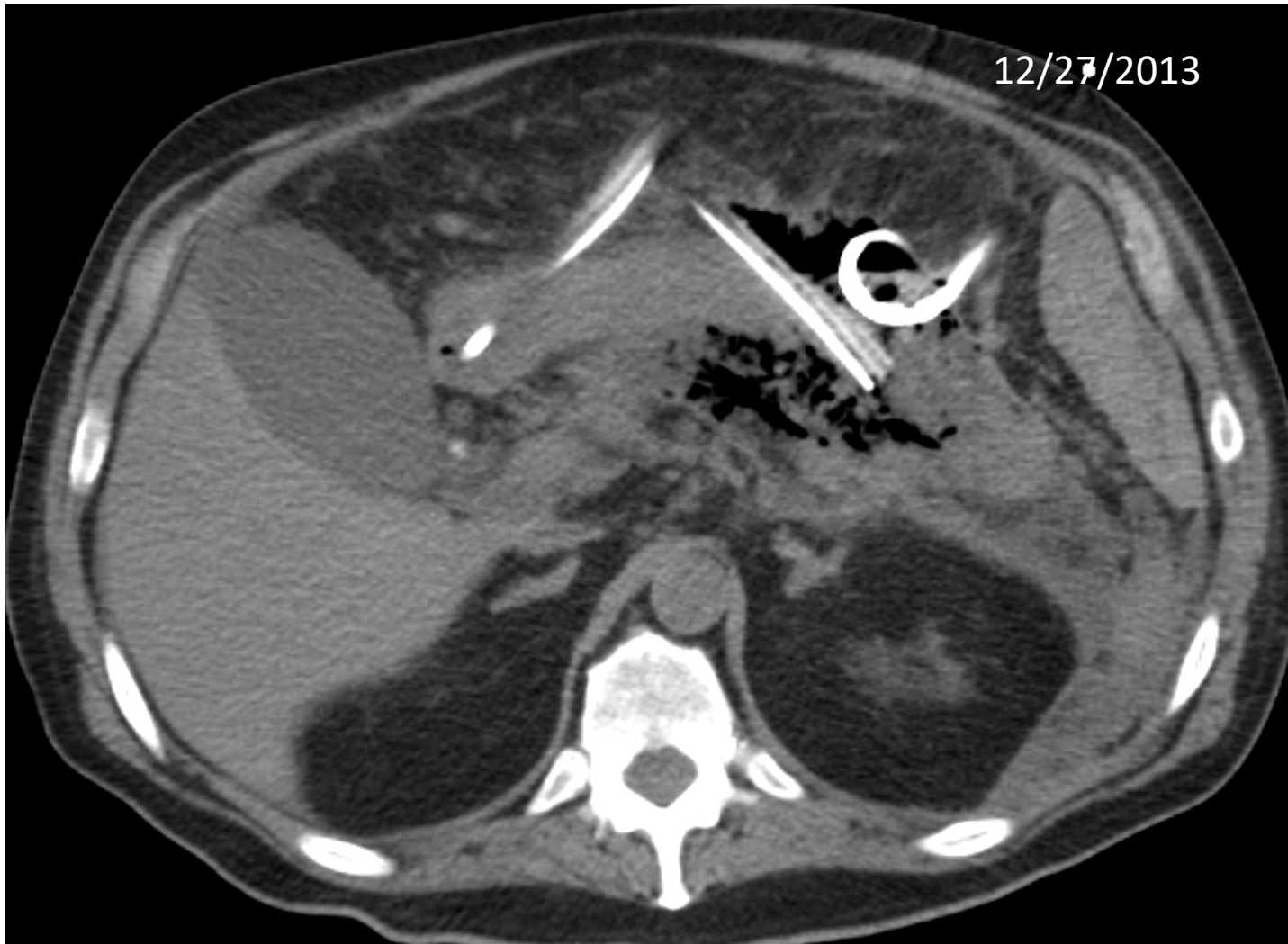- 58 M with diabetes mellitus, HTN, cholelithiasis, who was admitted with severe pain starting yesterday evening. The pain was bandlike in his epigastrium and 'off the charts' in intensity
- EMT was called and patient was brought to the ER. Abdomen was “exquisitively tender” to even light touch with EKG leads
- Initial labs showed amylase >4800, lipase 14580, triglyceride 21
- CT showed pancreatitis, no biliary dilation, gallstones. Ultrasound showed fatty liver, gallstones, CBD 0.6 cm
- Admitted to the ICU after receiving IVF and pain medications



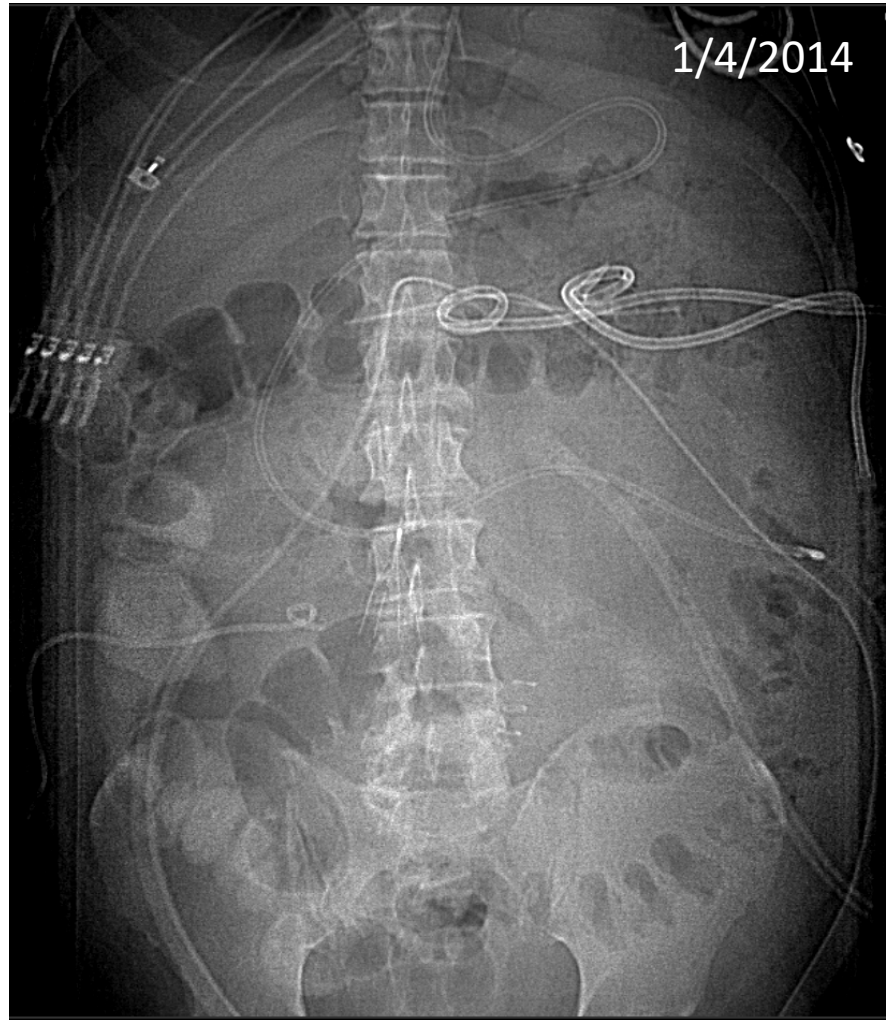One week later



2.5 weeks after that,



By this time, there were at least 5 drains



Hospital Course

- Underwent at least two surgical debridement and multiple drain placement throughout the abdomen
- Had ERCP for CBD stone removal
- EUS attempted for fluid/abscess drainage, but without a large enough pocket for drain placement
- After 6 months, discharged home with a percutaneous drain



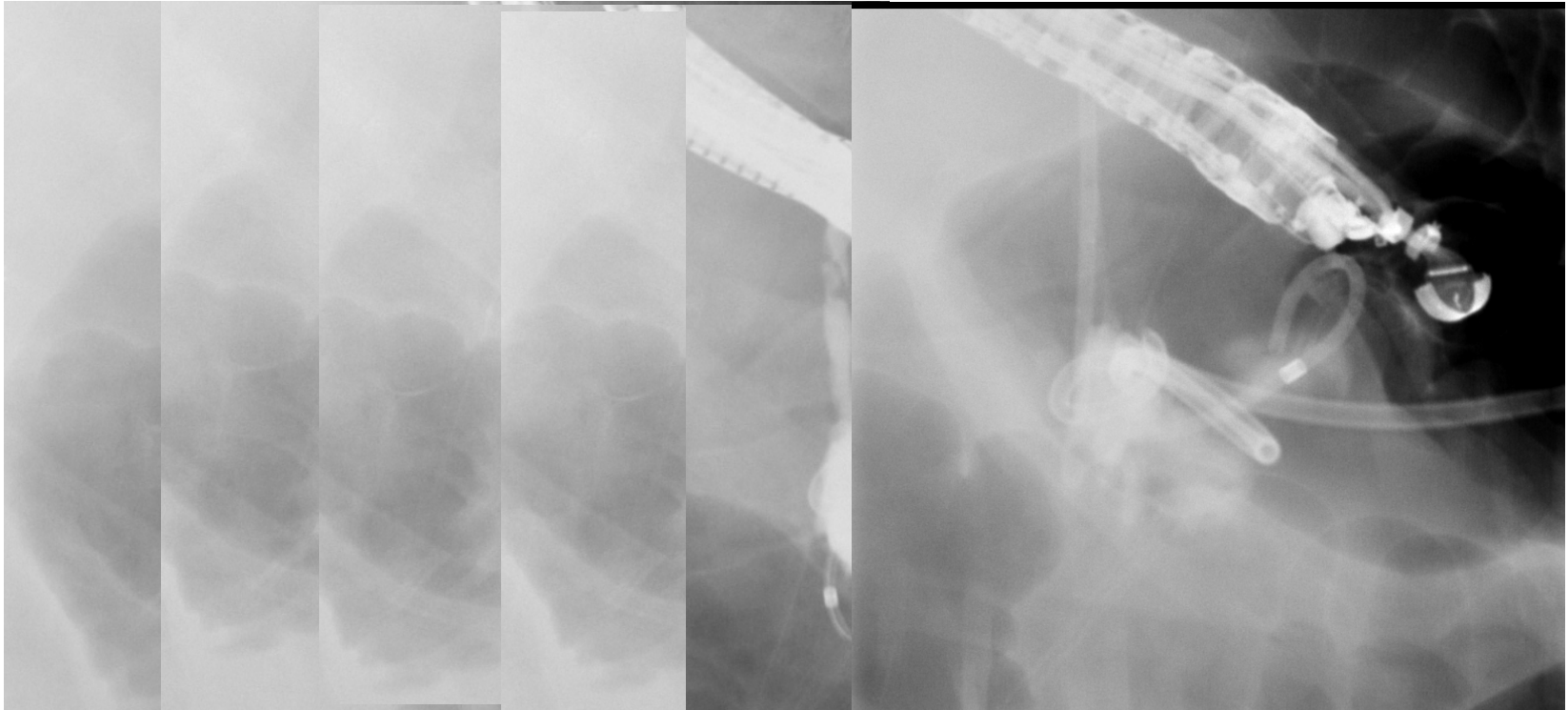
Outpatient Course

- Persistent leak around the drain
- Intermittent suggestions of infection around the drain, with cellulitis and drainage
- Tender and uncomfortable all the time
- Unable to work for almost 1.5 years
- Surgeon again requested for an idea to remove the external drain and close the fistula
- How?



Attempt to internalize the drain

6/22/2015



Internal stenting from stomach to PD

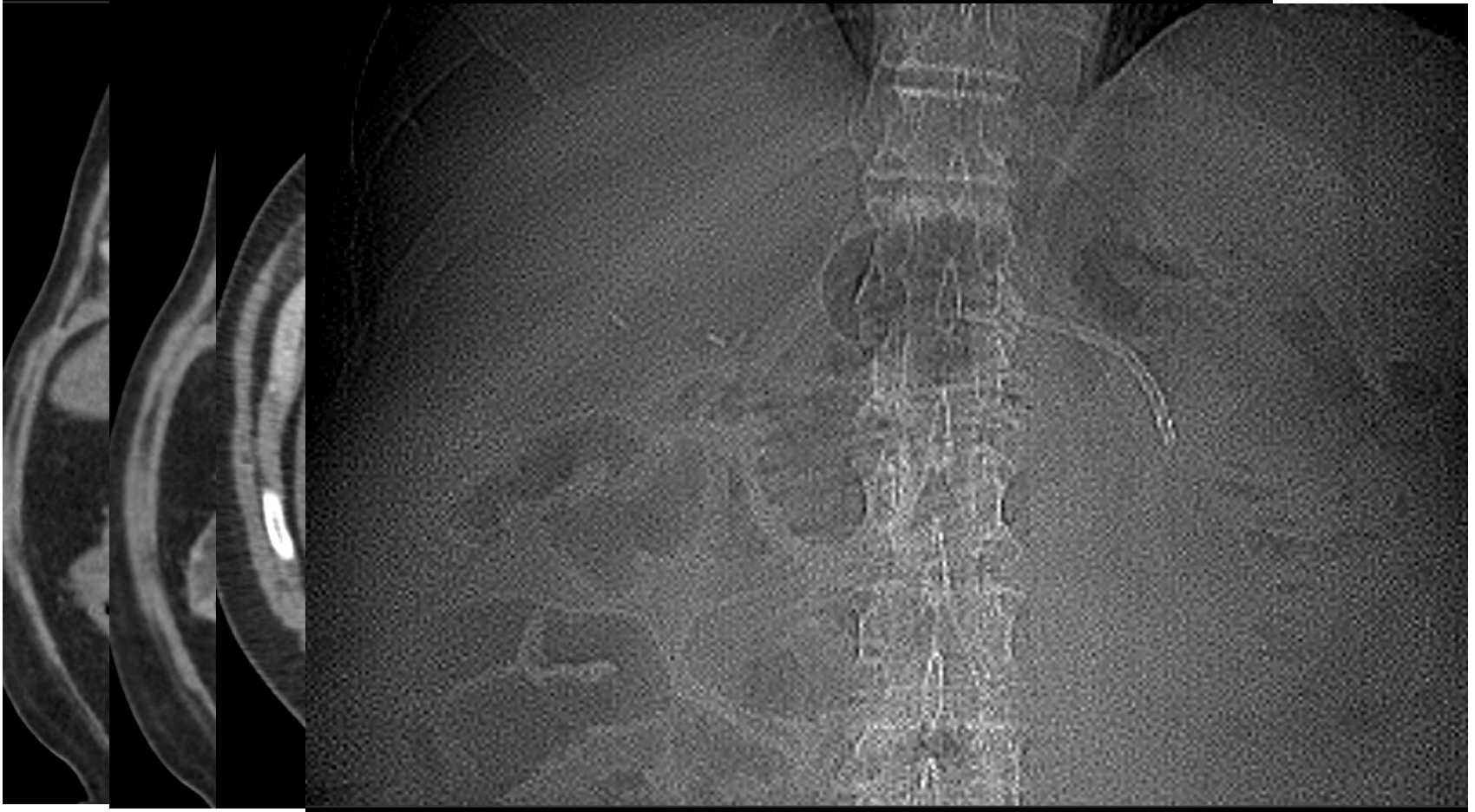


Further Out-Patient Course

- Within 2 weeks of internal stenting, no more leak via the percutaneous drain
- External drain removed
- Did great. Happy. Resumed normal activities
- In June 2016, one year later, patient complained of some mid/lower abdominal pain



CT Scan for Mild Abdominal Pain 6/2016



Discussion

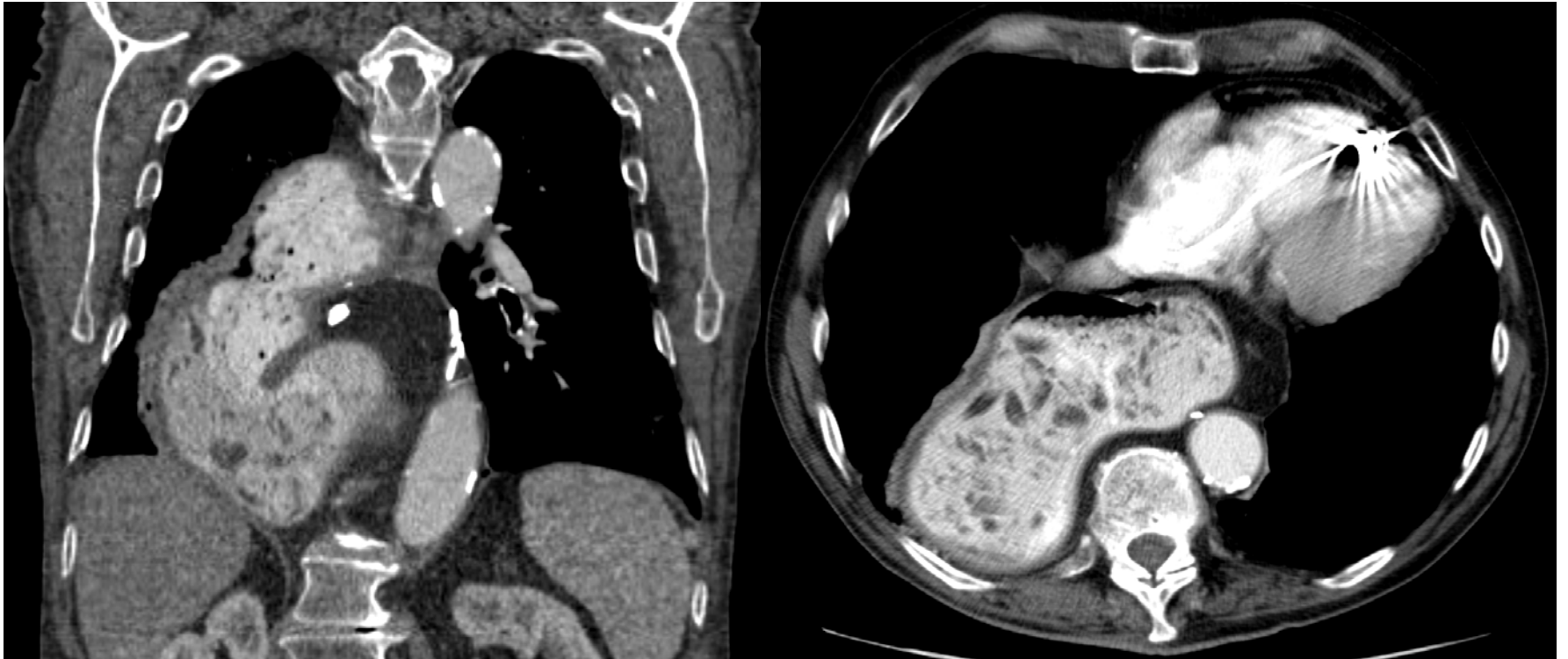

Recurrent Vomiting and Aspiration

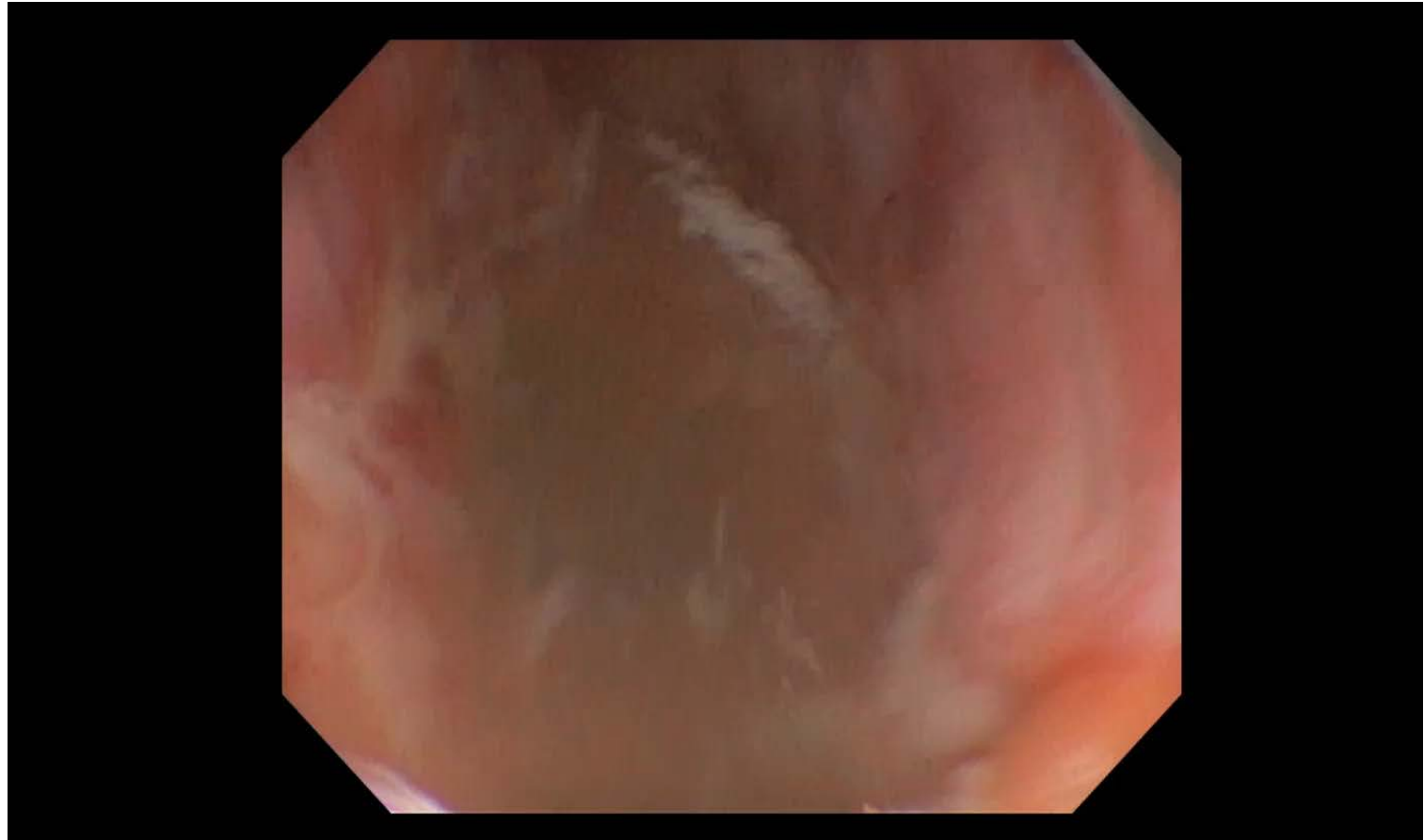
- 82 year old male diagnosed with adenoCA of distal esophagus, underwent resection in 2012
- Gradually developed dysphagia soon after the surgery. EGD showed no anastomotic stricture
- Then experienced progressive trouble with each meal and bouts of aspiration pneumonia
- Found to have food retention in the stomach. Coughing all the time
- EGD was aborted because of a large amount of food
- Failure of the pylorus to relax was thought to be the source of gastric retention. Had 1 successful Botox injection treatment, but that only lasted for a few days
- Refused surgical treatment

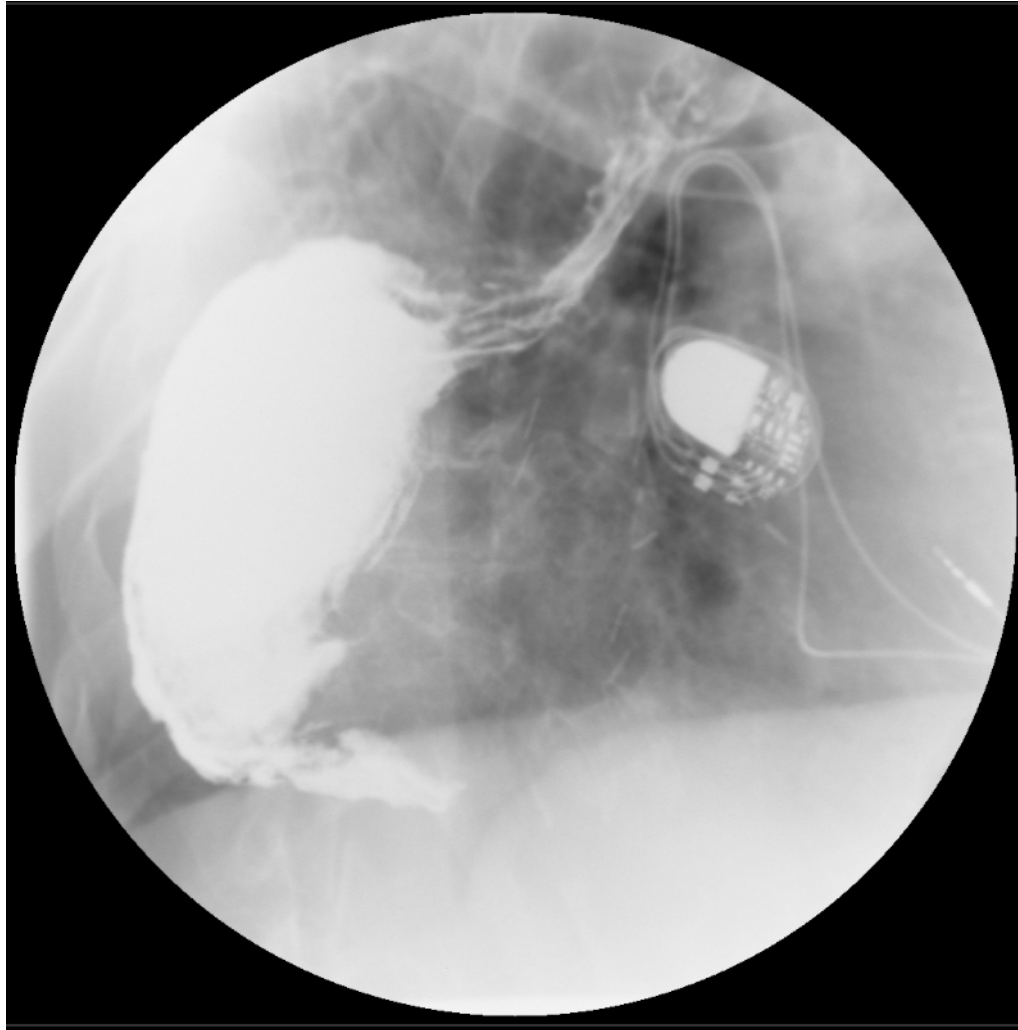


CT study



Post Esophagectomy Gastric Retention





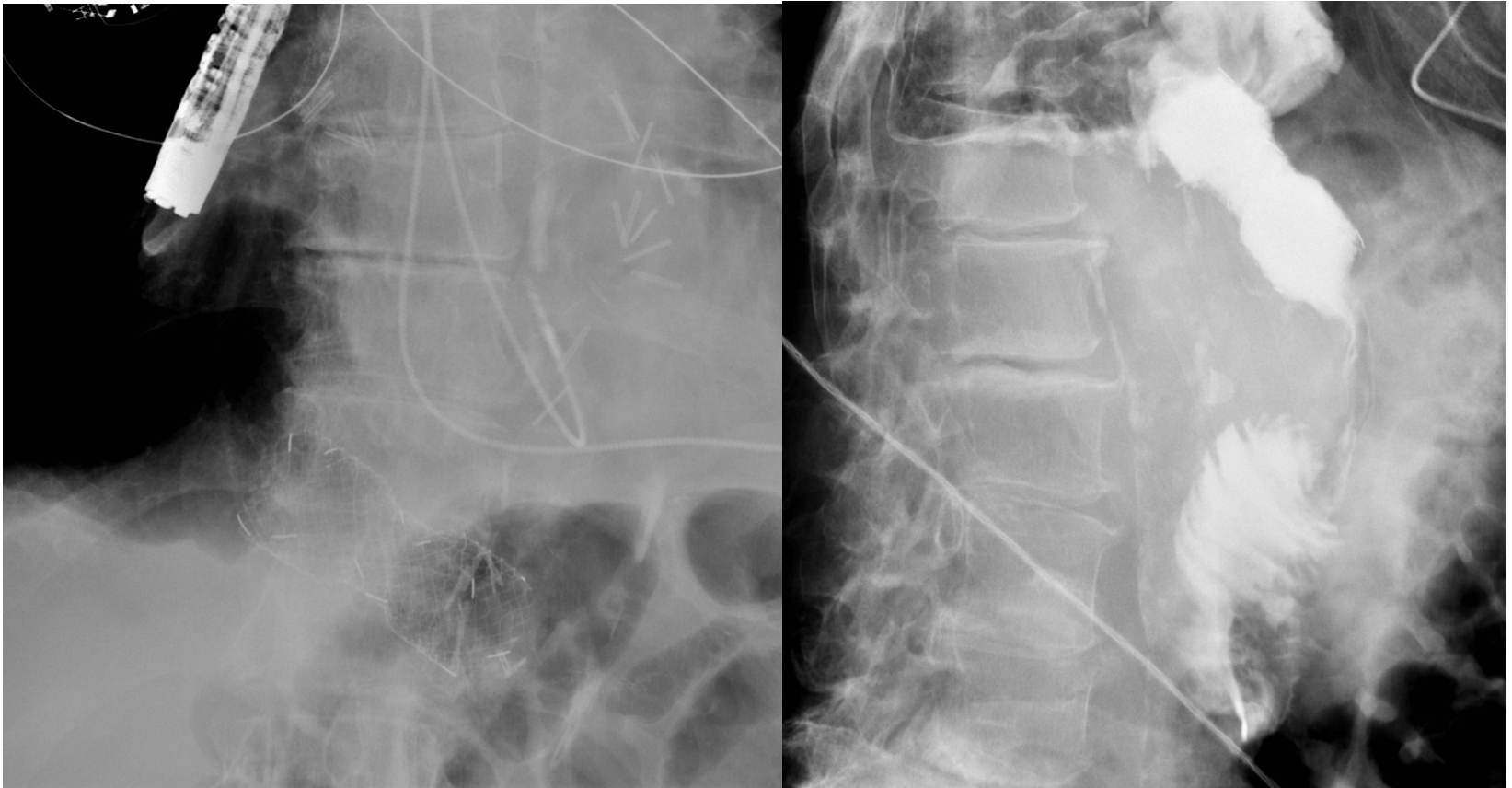Post-DDW 2019

What to do next?

- Keep stent in forever?
- Go for surgery (pyloroplasty)?
- Remove and replace, when needed?
- Perform G-POEM?



The latest!



Discussion



Motorized Spiral Enteroscopy



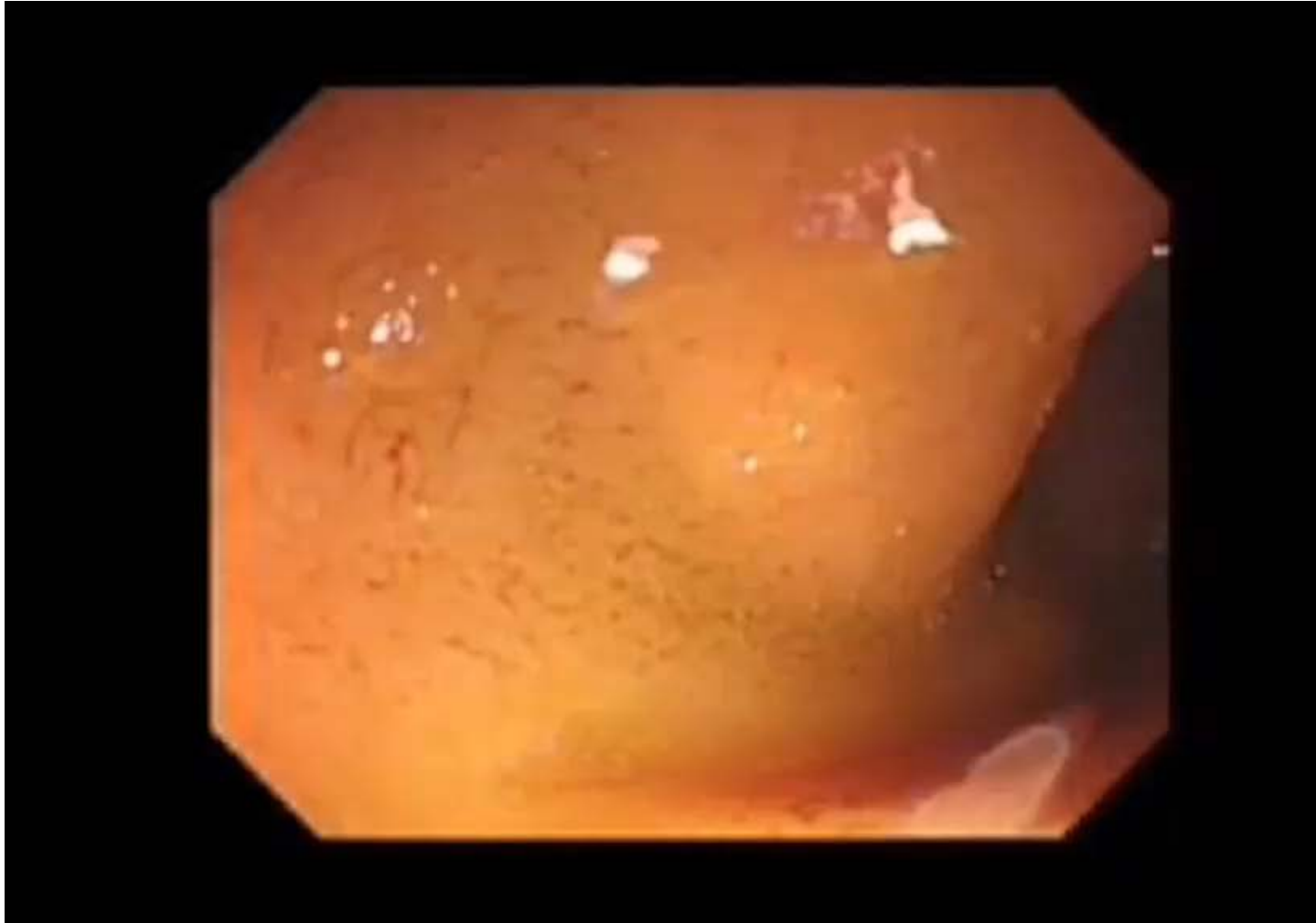
Post-DDW 2019

Nauhaus. Video GIE 2016

Discussion



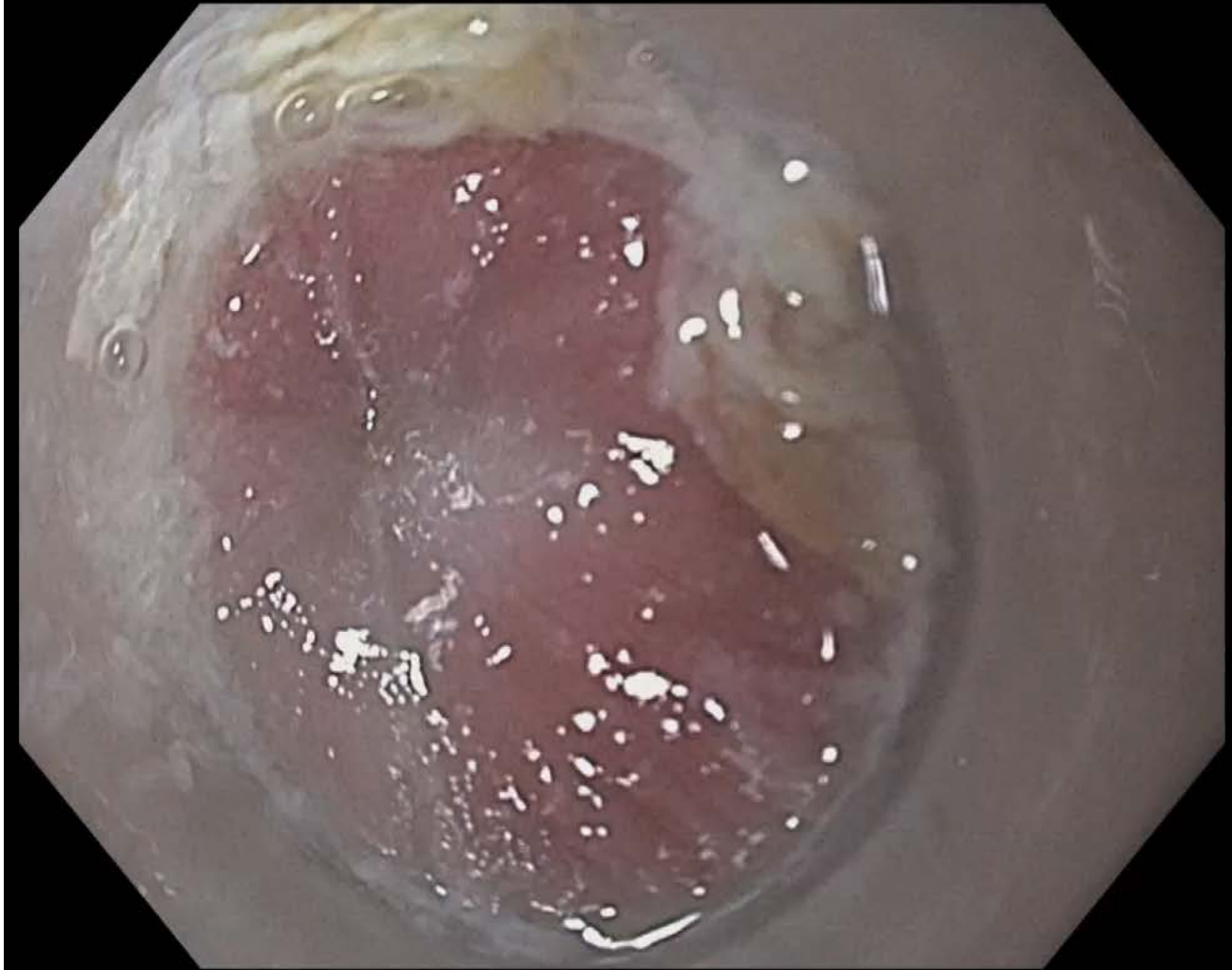
Endoscopic Gastrojejunostomy



Discussion



26 yo female with acute dysphagia



Discussion

